

Surgery Illustrated – Surgical Atlas

Robotic repair of vesicovaginal fistula (VVF)

Rene Sotelo, Vassilis Moros*, Rafael Clavijo and Vassilis Poulakis*

Department of Urology, La Floresta Medical Institute, Caracas, Venezuela; and *Department of Urology, Metropolitan Hospital, Athens, Greece

ILLUSTRATIONS by STEPHAN SPITZER, www.spitzer-illustration.com

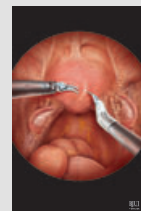
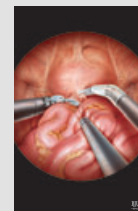
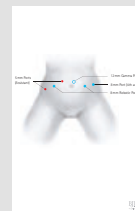
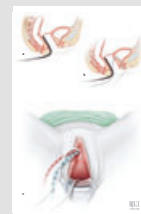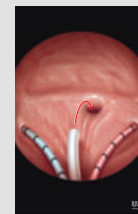

INTRODUCTION

For centuries, vesicovaginal fistula (VVF) has presented a challenge for surgeons and a significant social and hygienic problem for patients, especially when it recurs or leads to severe complications [1].

While worldwide, the predominant cause of VVF is obstructed labour due to poor obstetric care, in obstetrically developed countries this is usually an iatrogenic complication of gynaecological surgery, most commonly abdominal hysterectomy, occurring in one in every 1800 hysterectomies [2–4]. Generally, VVF occurs 1–6 weeks after gynaecological or obstetric surgery, while recurrent fistula can develop within the first 3 months after primary repair [2].

The proper timing for corrective surgery and the ideal type of procedure is currently controversial [5]. The early vs delayed repair of VVF has been debated. In select cases, early reconstruction is favourable [6]. Although a trial of conservative therapy including proper and undisturbed bladder drainage for several weeks, treatment with antibiotics when indicated and in some cases a fulguration attempt of a small fistulous tract should be tried, the probability of spontaneous closure of VVF is low (7–12.5%) [3,4].

When VVF is large or does not respond to conservative measures, surgical correction is indicated, with a success rate of 75–97% in cases of fistula resulting from surgical injury [3–5]. Various surgical techniques have been proposed for repair of VVF, depending on the cause, location and surgeon's experience. As most VVFs result from difficult



hysterectomy, the initial repair is usually attempted transvaginally, mostly because this approach has less morbidity and it is more familiar to gynaecological surgeons [3]. However, the vaginal exposure has its limitations, especially when the VVF is high lying on the posterior bladder wall and the vagina severely scarred [5]. Although the morbidity of open abdominal repair is significant compared with that of the transvaginal approach, abdominal surgery is usually preferred in patients with a large (>3 cm) or supratriangular

fistula or a fistula in close proximity to ureteric orifices and especially in patients with multiple complicated or recurrent VVF after transvaginal repair [7,8].

To decrease the morbidity of the abdominal approach, a laparoscopic repair of VVF has been used, which is primarily associated with similar success rates, minimal surgical trauma and lesser morbidity, thus allowing more rapid convalescence [9]. Despite initial enthusiasm, laparoscopy has not gained in popularity, probably because laparoscopic VVF dissection and intracorporeal suturing are technically challenging. Robotic assistance in complex laparoscopic procedures has overcome the technical difficulties of the laparoscopic approach, even in challenging cases of recurrent VVF [10]. Using the technological advantages of robotic technology (EndoWrist™ instruments with increased degrees of freedom leading to improved dexterity and absence of fatigue, three-dimensional [3-D] vision with improved depth perception, motion scaling, tremor filtration, higher magnification, and surgeon's ergonomic position in a long-standing and time-consuming operation), it is possible to perform a repair of VVF laparoscopically, respecting the basic surgical principles of fistula reconstruction [4,6,8], namely:

- 1) clear and wide exposure of the fistula track and surrounding tissue
- 2) circumferential excision of fibrous and scar tissue from the fistula edges
- 3) saving both ureteric orifices
- 4) use of suitable suture material
- 5) individual tension-free suture repair of freshened fistula edges in the vagina and the bladder
- 6) watertight, multiple-layer closure
- 7) non-overlapping suture lines
- 8) interposition of various well-vascularised tissues, such as omentum [11], peritoneum, bladder flap taken from a site away from the fistula or epiploic appendix taken from the sigmoid colon
- 9) continuous and adequate postoperative bladder drainage, especially early after repair

PLANNING AND PREPARATION

INDICATIONS AND CONTRAINDICATIONS

The indications for robotic repair of VVF are the same as those for open abdominal

surgical correction. Although most VVF in the developed and industrialized world are amenable to transvaginal repair, there are certain indications for an abdominal approach [3–5], such as:

- 1) inadequate exposure related to a high or retracted fistula in a narrow vagina
- 2) close proximity of the fistulous tract to the ureter
- 3) associated pelvic pathology, e.g. an associated ureteric injury (e.g. ureterovaginal fistula) or a complex fistula involving another intra-abdominal organ
- 4) multiple fistulae

Nevertheless, a previously failed transvaginal attempt at repair of VVF is not necessarily a contraindication for a new transvaginal approach as excellent results can be achieved in this setting [6].

Absolute contraindications are massive haematoma in the pelvis and active UTI.

SPECIFIC PATIENT PREPARATION

Although the mechanical (with polyethylene glycol and a liquid diet of 4–5 L) and antibacterial bowel preparation the day before surgery is not absolutely necessary, we still routinely use it, especially in cases of complicated VVF. A prophylactic dose of heparin (low molecular weight adjusted to the body weight of the patient) is given the evening before surgery and every 24 h thereafter until ambulation. Before the operation begins, all patients are shaved from nipples to mid-thighs. As infection prophylaxis is essential for surgery outcome, antibiotics with amoxicillin/clavulanic acid and metronidazole orally are commenced 1 day before the operation and continued parenteral when the procedure begins. Metronidazole is continued for 48 h and amoxicillin/clavulanic acid until all drains and catheters are removed.

SPECIFIC EQUIPMENT AND MATERIALS REQUIRED FOR ROBOTIC REPAIR OF VVF

Robotic equipment (da Vinci, Intuitive Surgical, Mountain View, CA, USA):

- Three (for four-arm robotic system) or two (for conventional three-arm device) trocars (8 mm)

- 0° and 30° 3-D laparoscope
- Hot Shears™ (monopolar curved scissors)
- Maryland bipolar forceps
- Two large needle drivers
- Two ProGrasp™ forceps

Laparoscopic equipment:

- One trocar (12 mm) for the robotic telescope
- Two trocars (5 mm) for the bedside assistant
- 5-mm endoscopic long suction irrigator (45 cm)
- 5-mm endoscopic scissors
- 5-mm endoscopic locking grasper
- 5-mm endoscopic needle driver

Energy sources/haemostatics:

- Monopolar/bipolar electrocautery
- 5.5-mm Ethicon UltraCision harmonic scalpel coagulating shears, pistol grip (36 cm, 15-mm active blade – 5.5 mm diameter)

Suture materials:

- 3-0 poliglecaprone 25 monofilament synthetic absorbable suture (Ethicon, Monocryl™) with RB-1 needle (half circle, 17 mm diameter) for bladder and vagina closure. Alternative 3-0 glycomer 631 monofilament synthetic absorbable suture (Biosyn™) with CV-25 needle (half circle, 22 mm diameter).
- 2-0 polyglycolic acid, braided suture with round-bodied needle (half circle, 30 mm diameter) using as fixation/anchor suture for the interposition graft (omentum or peritoneal flap)

Other materials:

- Two long mono-J ureteric stents 7 or 6 F with guided wire (Bander Ureteral Diversion Stent Set, Cook Urological, Inc., Spencer, IN, USA)
- Simple ureteric catheter 5 F for retrograde visualisation of ureters with contrast medium and for canalisation of VVF
- Silicon Foley catheter 22 F
- Cystourethroscope 22 F with a ureteric catheterisation bridge (30° telescope)
- C-arm device for assessing the proper placement of ureteric catheters

SPECIFIC PATIENT POSITIONING

Figure 1

The positioning of the patient is the same as for cystoscopy and robotic radical prostatectomy. The patient is placed supine on the operating table. Anatomic pillows protect the head and shoulders. To avoid neuromuscular injury, the patient is adequately padded and supported with great care. To prevent hypothermia, elastic cotton drapes are wrapped around the extremities over the anti-thrombotic elastic socks and a special warm air blanket covers the patient's face and chest. The patient is placed in the lithotomy position and the legs are inserted in special boots, which facilitate the active legs positioning during the procedure. The robot is placed between the patient's legs. Thus, these should be positioned with maximum separation to facilitate robot docking and digital manipulation of the vagina by the assistant during the procedure.

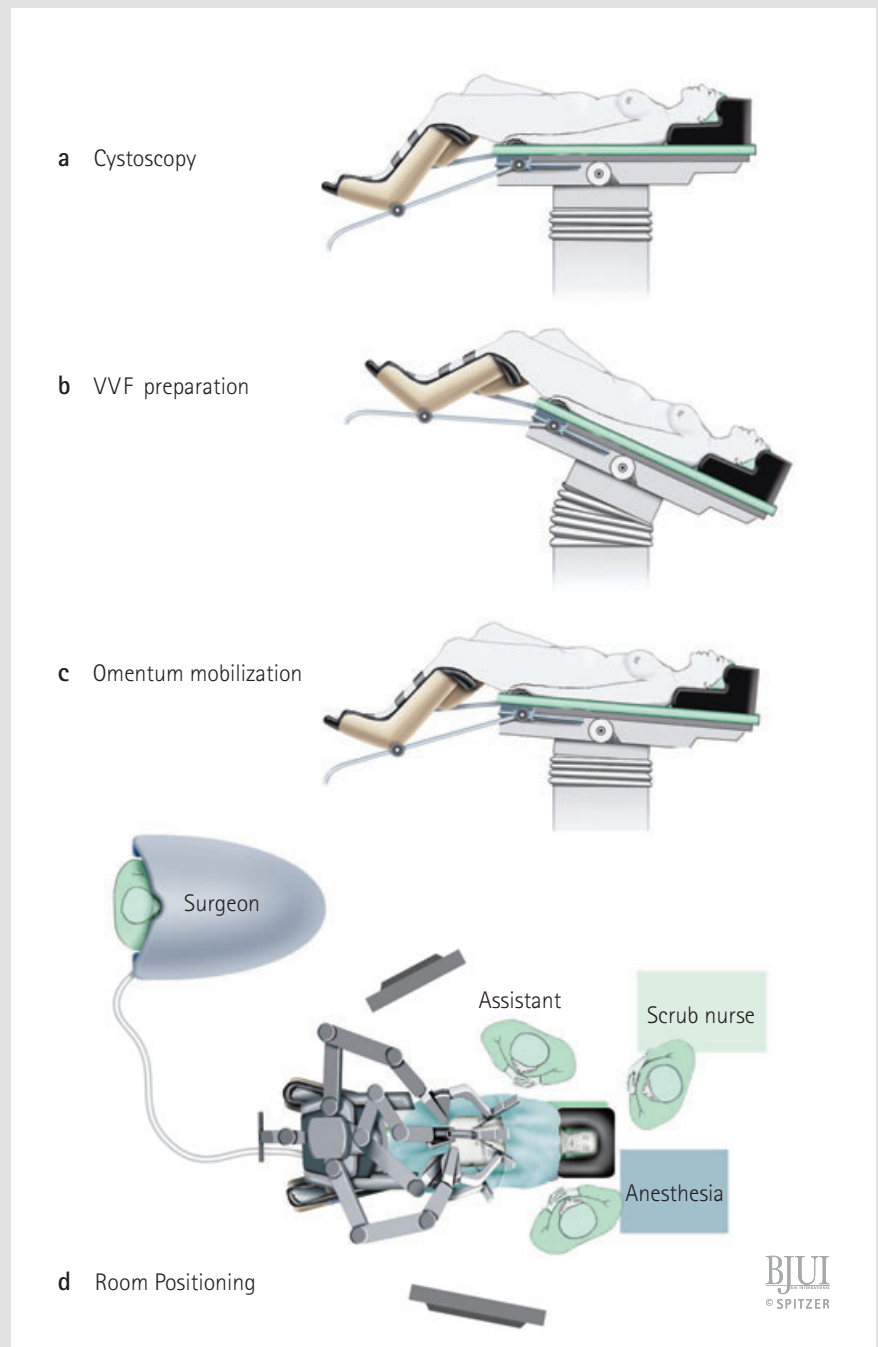
During the various surgical steps, the patient is placed in different special positions.

A. During cystoscopy the patient is placed in the classical lithotomy position with the operating table positioned horizontally and taking great care to facilitate the movement of the C-arm between the kidney and bladder area.

B. During the initial phase of VVF preparation the operation table is placed in a steep Trendelenburg position to facilitate adhesiolysis and keep the Douglas pouch free of sigmoid colon and small intestine, in order to have complete access to the vagina and bladder.

C. Finally, to commence the omentum mobilisation for tissue interposition, the patient is placed back in an almost horizontal position, parallel with the floor (0–5°), thus contributing to the performance of tension-free fixation of the omentum and helping to keep the small bowel contents in the epigastrium. Additionally, the hips and the knees are only slightly flexed to reduce the distance between the mesentery root and os pubis, facilitating a tension-free approximation of omentum to the VVF area.

D. Any da Vinci system could be used but the new systems (i.e. da Vinci-S HD System with four arms or higher) are preferred. Using the new systems, the trocars can be



placed relatively independent of the patient's somatotype and higher, which is very important in cases with difficult mobilisation of the omentum.

CYSTOSCOPY AND URETERIC CATHETER PLACEMENT

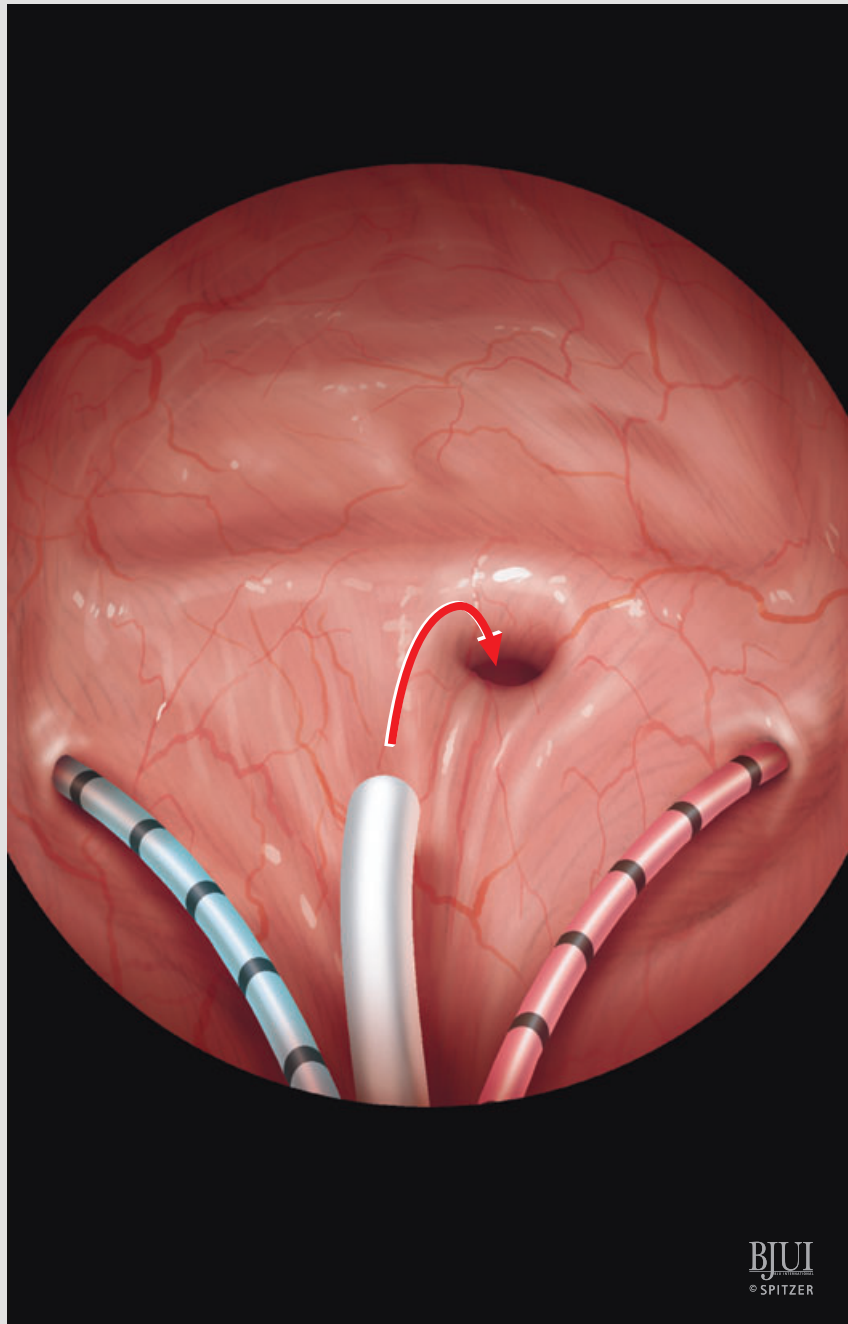
Figure 2

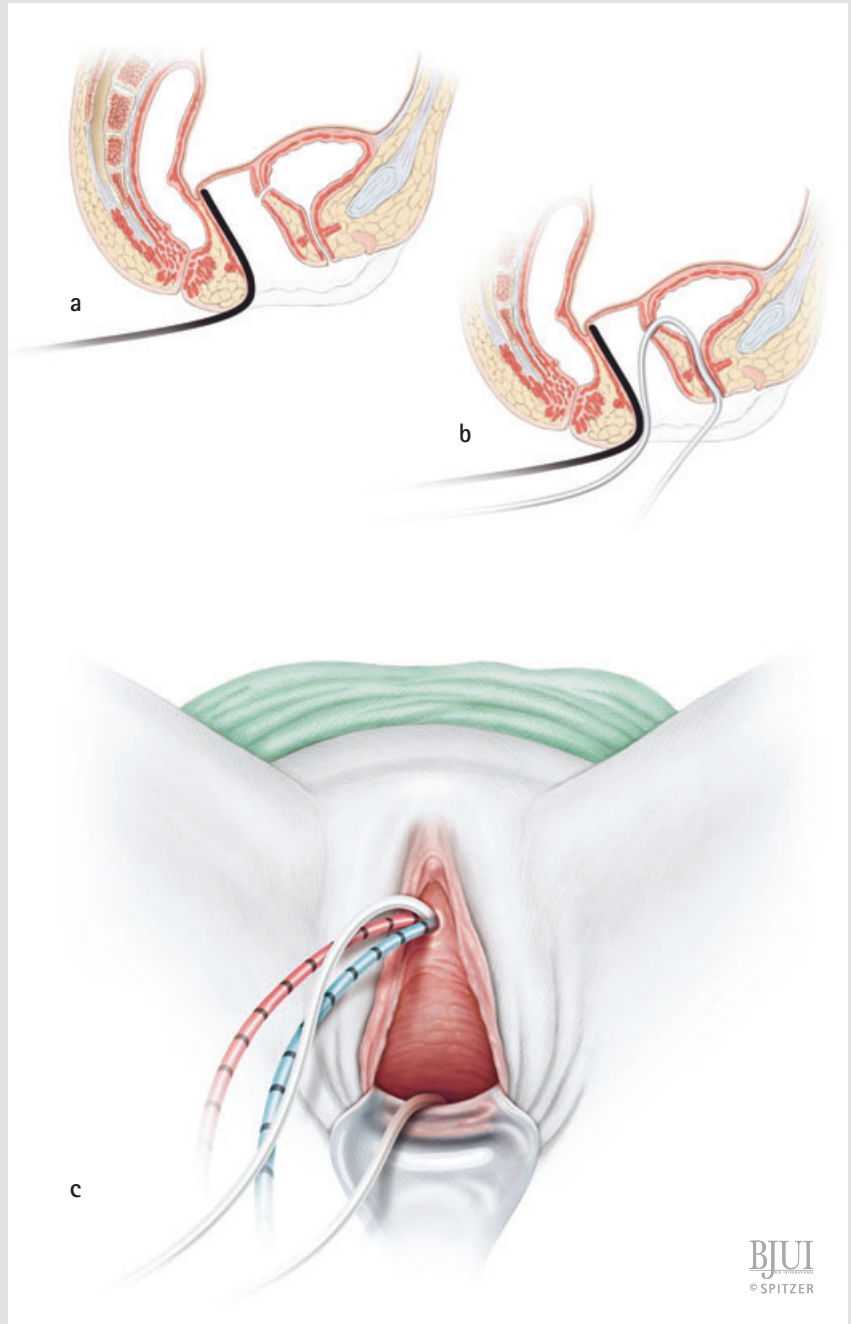
Cystoscopy is performed and the two ureters are catheterised using mono-J ureteric catheters of different colours for each side. Thus ureteric identification and protection during excision and closure of the VVF is guaranteed.

CYSTOSCOPY – VAGINOSCOPY AND PLACEMENT OF CATHETER IN FISTULA AS A MARKER

Figures 2 and 3

To facilitate identification of VVF, a simple ureteric catheter of a colour different to those used for the ureters is pulled cystoscopically through the fistula into the vagina and retrieved outside through the vaginal introitus. In case of a large VVF tract, a Foley catheter is inserted rather than a ureteric catheter. This Foley catheter marker is placed transvaginal through the wide fistula tract and blocked with 5 mL saline. A sponge retractor or alternative vaginal tamponade is inserted into the vagina up to the vaginal apex.





BJU
© SPITZER

SPECIFIC PORT POSITIONING

Figure 4

After ureteric catheter placement, the patient is placed in a steep Trendelenburg position and the ports are inserted as follows:

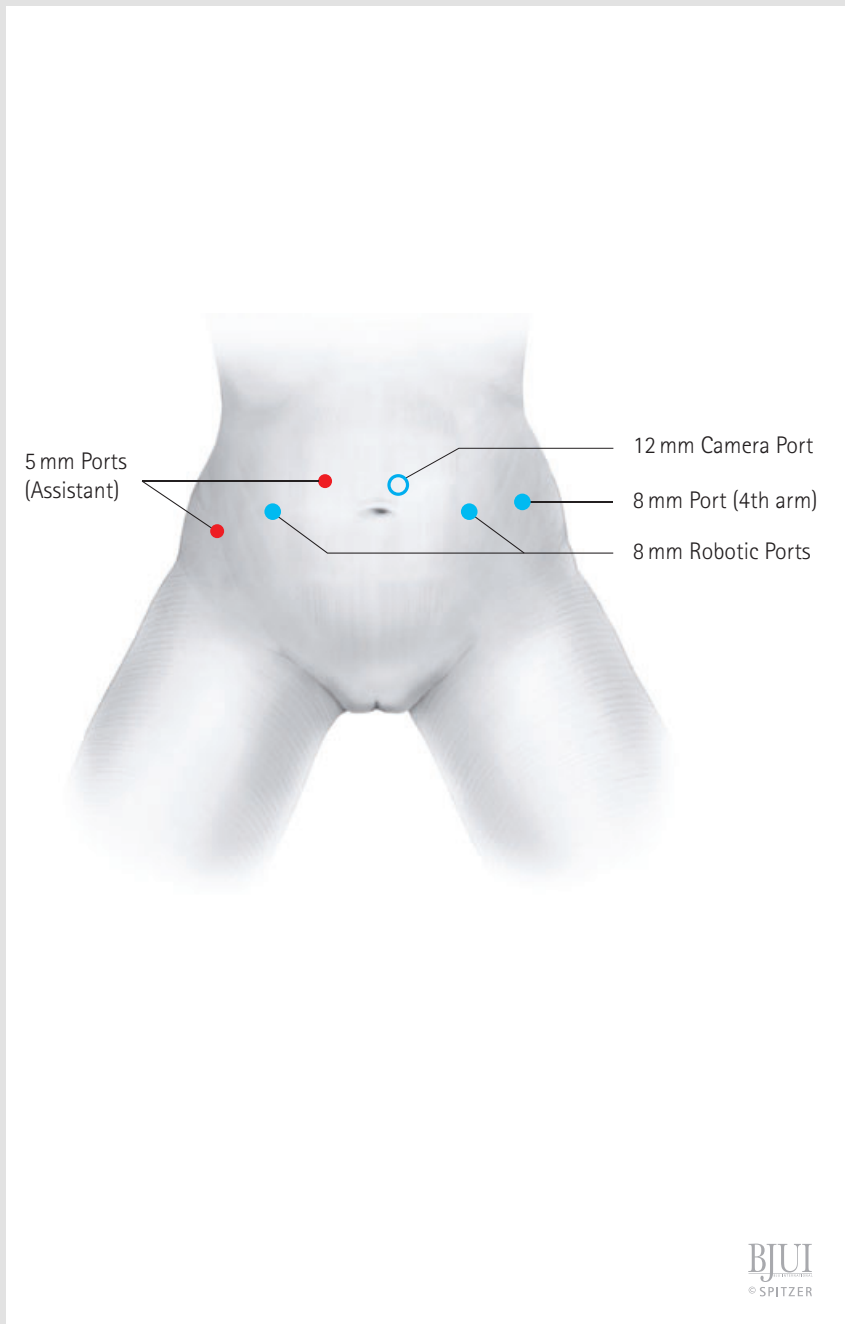
- First, a 12-mm optic port is placed 3–5 cm above the umbilicus and 1–2 cm left of the middle line, depending on the length of the patient.

At the umbilicus level, two robotic 8-mm ports are placed symmetrically on the left and right pararectal line.

If using a da Vinci device with a fourth arm, an 8-mm robotic port is placed up from the iliac crest on the left side. In case of absence of a fourth arm, no additional port is placed on the left side. The right-side port can be used for insertion of suture materials with needles.

A 5-mm port up from the iliac crest on the right side.

A 5-mm port at the right side between the optic and the 8-mm port, for insertion of suction irrigation device.



PROCEDURE

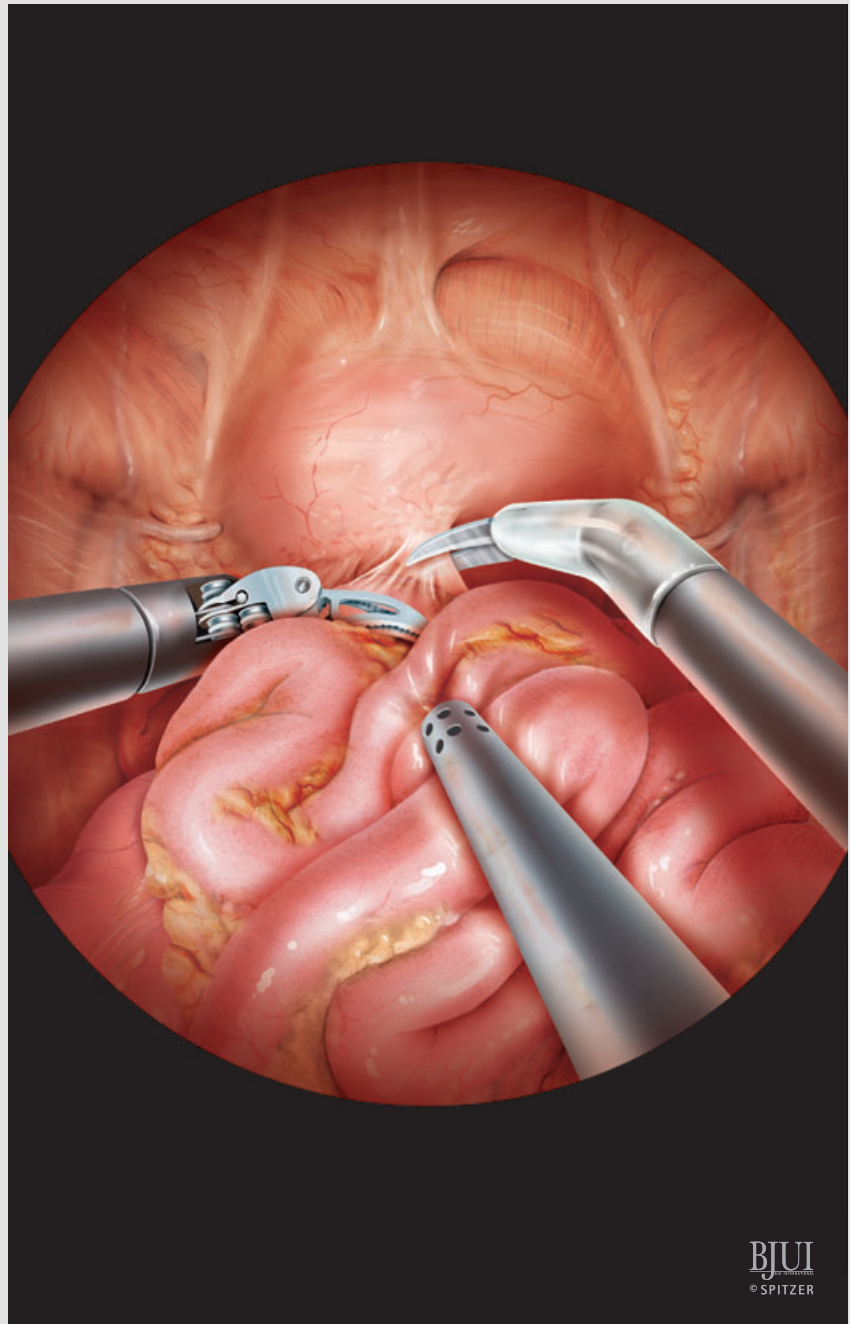
PERITONEOSCOPY AND ADHESIOLYSIS

Figure 5

After insertion of the first trocar, which is inserted preferably using the open Hasson technique, a peritoneoscopy is performed. After hysterectomy or any other gynaecological or general abdominal surgery (e.g. appendectomy etc.), the extent of postoperative adhesions vary, depending mostly on the surgical technique and perioperative inflammation and/or infection. In all cases a meticulous adhesiolysis of the bowel from the surrounding structures, especially in the Douglas pouch is necessary. Using a combination of sharp and blunt dissection with Maryland fenestrated bipolar forceps and monopolar curved scissors, further adhesiolysis is performed to expose the anterior surface of the uterus (if it is present, as all patients we have robotically operated had already gone through hysterectomy, so there was no uterus to be exposed) and the superior aspect of the bladder. The small bowel loops and/or the sigmoid colon usually require to be carefully dissected off the underlying bladder.

In a steep Trendelenburg tilt, intestinal contents are packed superiorly either by the assistant with a laparoscopic retractor or by the surgeon using the ProGrasp™ forceps. The adhesiolysis is extended until the rectovaginal (Douglas) pouch is completely free of any tissue content.

In some cases, the adhesions are so extensive that, even before robot docking, an extensive lysis of the adhesions close to the port sites is necessary laparoscopically. Subsequently, the robot can be docked.



BJUI
© SPITZER

LOCALISATION OF THE FISTULA

Figure 6

Before the cystostomy, the bladder is filled with 180 mL saline through the transurethral Foley catheter to facilitate anatomical identification of the bladder. Before the incision is carried vertically downward, the ureteric or Foley catheter that runs along the fistulous tract is manipulated by the bedside assistant and laparoscopically identified from the movement of bladder wall. Thus, a gentle drawing on the ureteric catheter, which passed through the VVF, is usually helpful for the location of the approximate site of the fistula as seen laparoscopically, allowing the creation of minimal cystostomy just above the adherent and fistulous area.

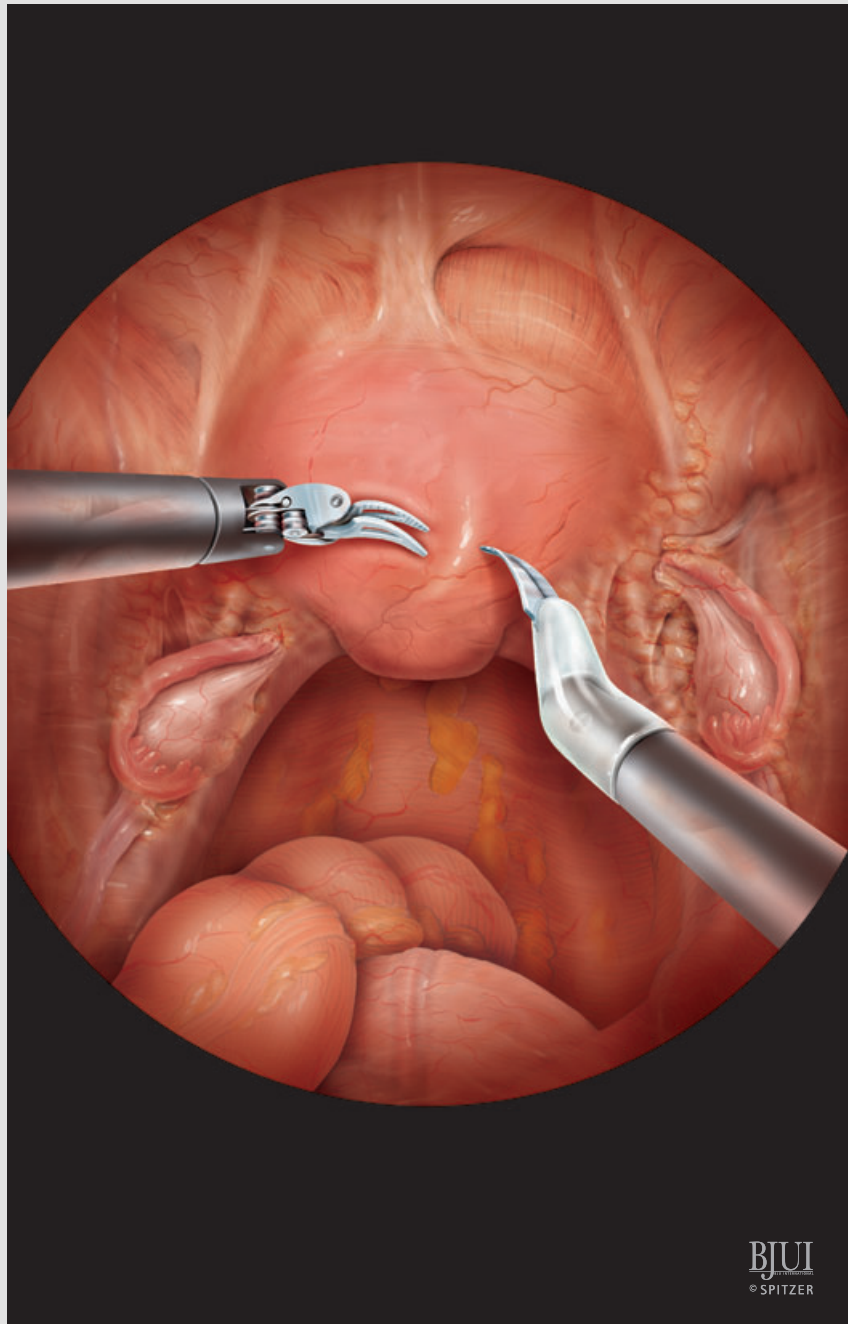
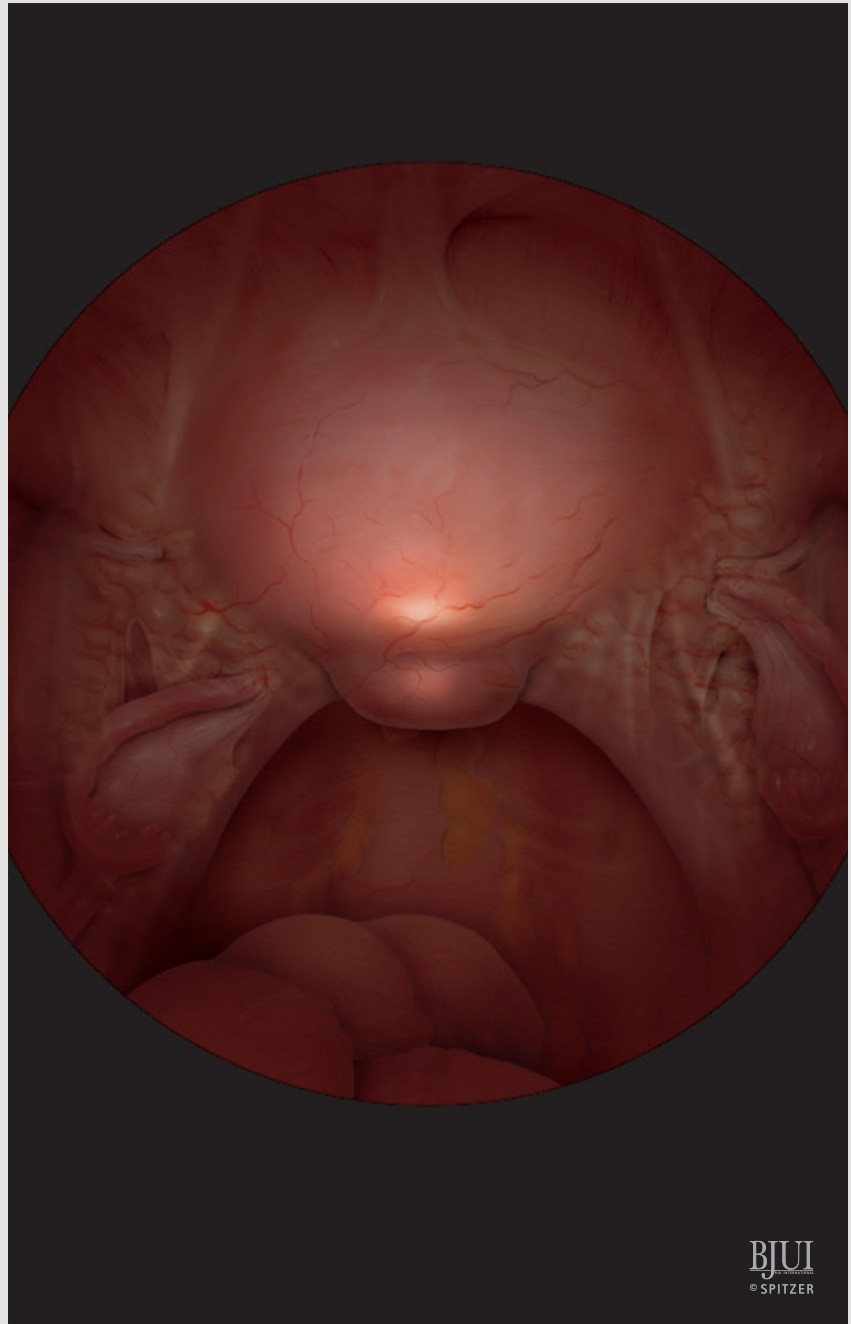
BJUI
© SPITZER

Figure 7

Alternatively, the VVF can be localised by diaphanoscopy, focusing the light of the cystoscope on the fistula, which becomes clearly visible laparoscopically through the bladder after switching off the robotic camera light.



BJU
© SPITZER

CYSTOTOMY

Figure 8

In direct proximity of the VVF, the posterior bladder wall is incised vertically with the monopolar robotic scissors. Then the cystotomy is continued in the direction of the catheter that defines the fistula, completely opening the posterior bladder wall. If the fistulous tract is relatively small and laparoscopically visible through the cystotomy, the vaginally placed ureteric catheter, which was used as a marker for the fistula, is cut and removed.

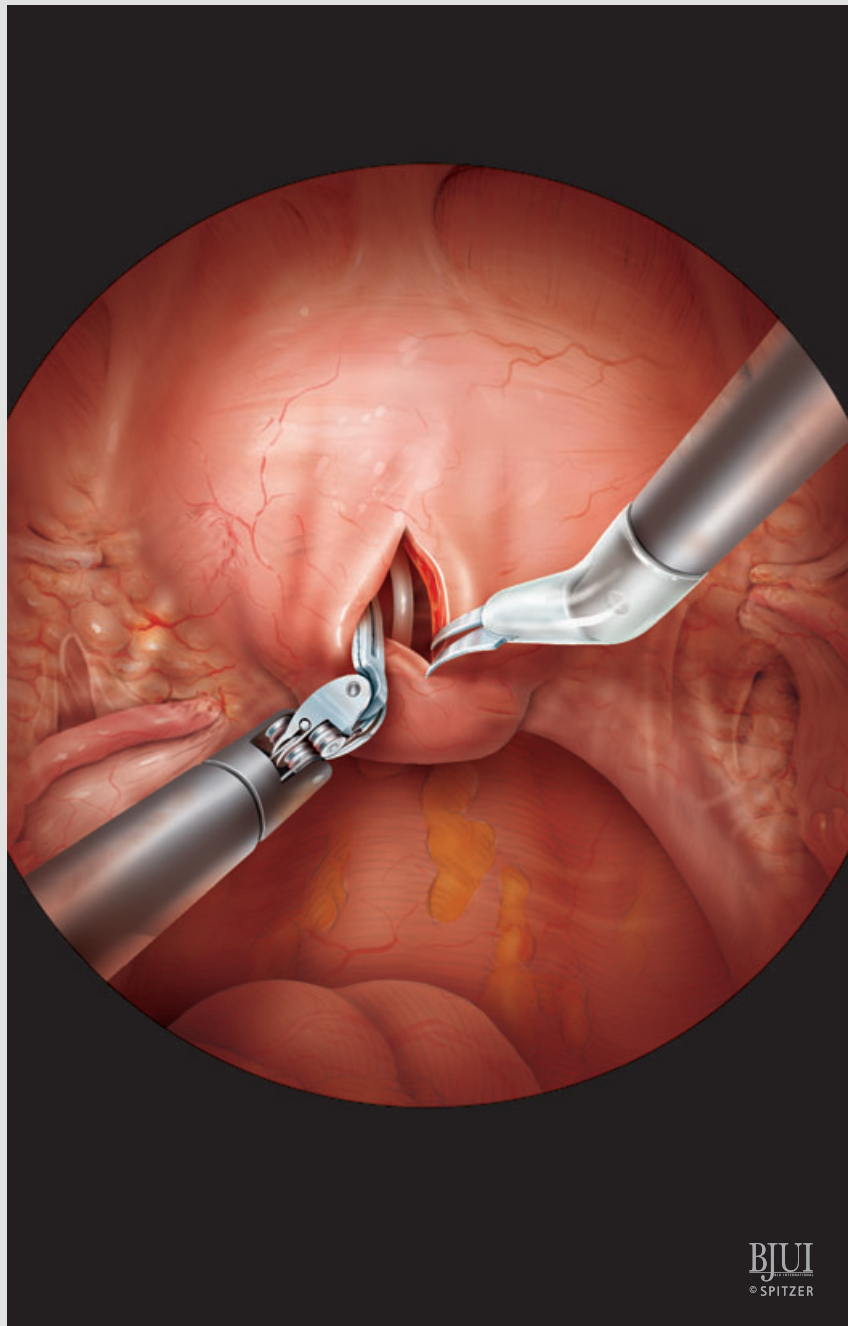
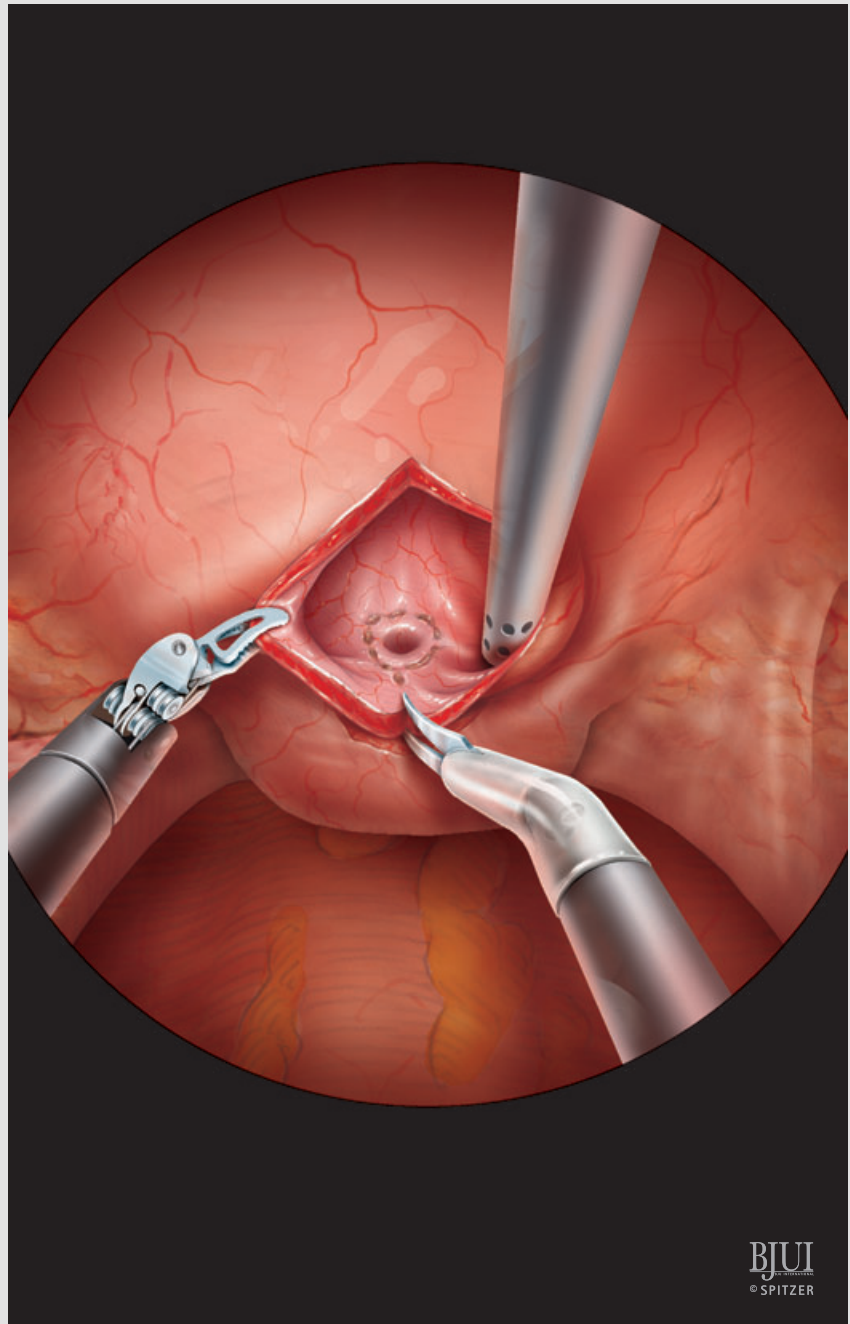
BJUI
© SPITZER

Figure 9

Margins of resection of fistulous tract are marked in the form of a 'tennis racket' by scoring the bladder mucosa with the monopolar robotic scissors.

If the fistula is large and/or not completely identified, then the vaginally placed Foley catheter is pulled intra-abdominally through the cystostomy and used as a retractor for the anterior bladder wall to splint open the cystostomy thus allowing better visualisation of the fistula and the stented ureteric orifices.

Loss of pneumoperitoneum is avoided by clamping the Foley catheter at the external site and packing the vagina with a wet sponge.

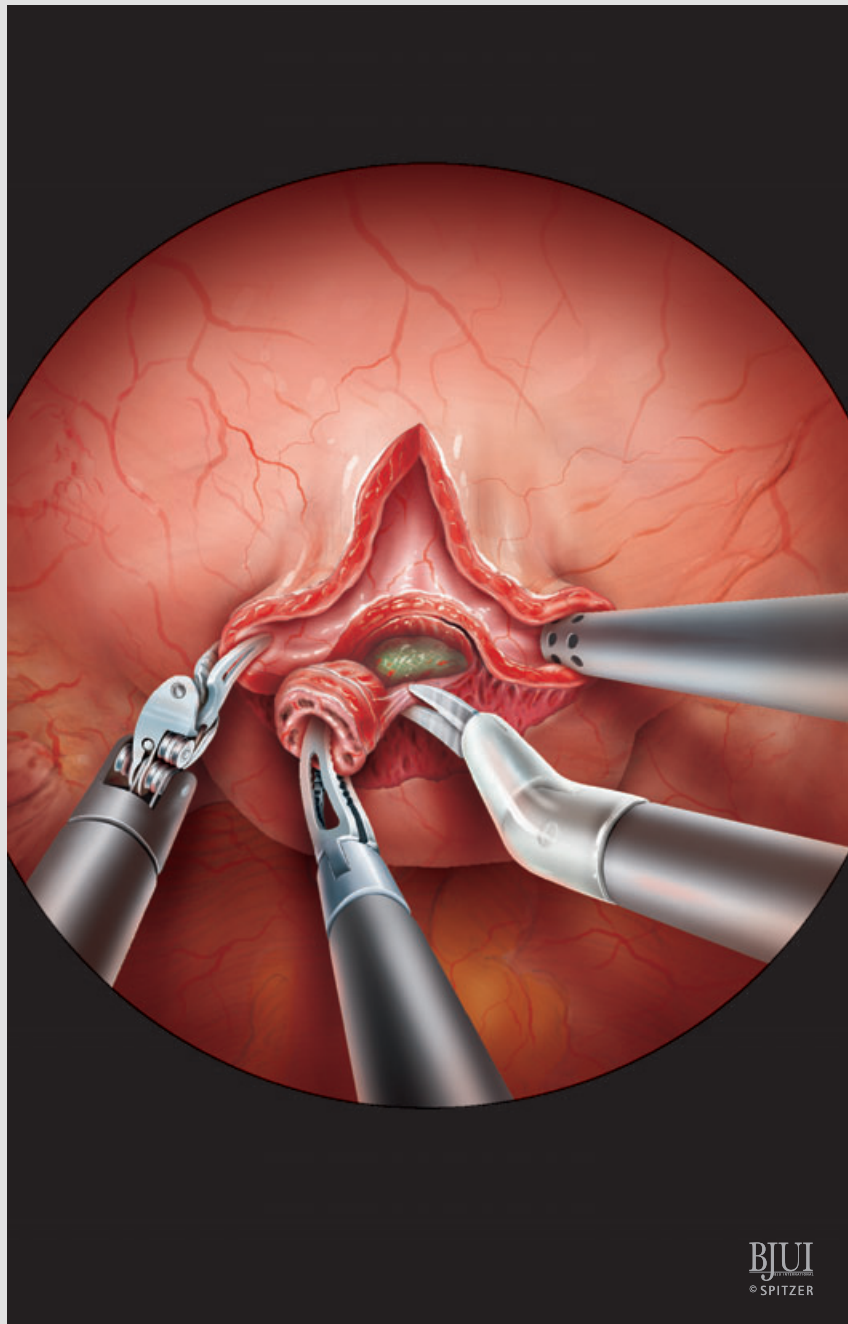


BJU
© SPITZER

FISTULA AND NECROTIC TISSUE EXCISION

Figure 10

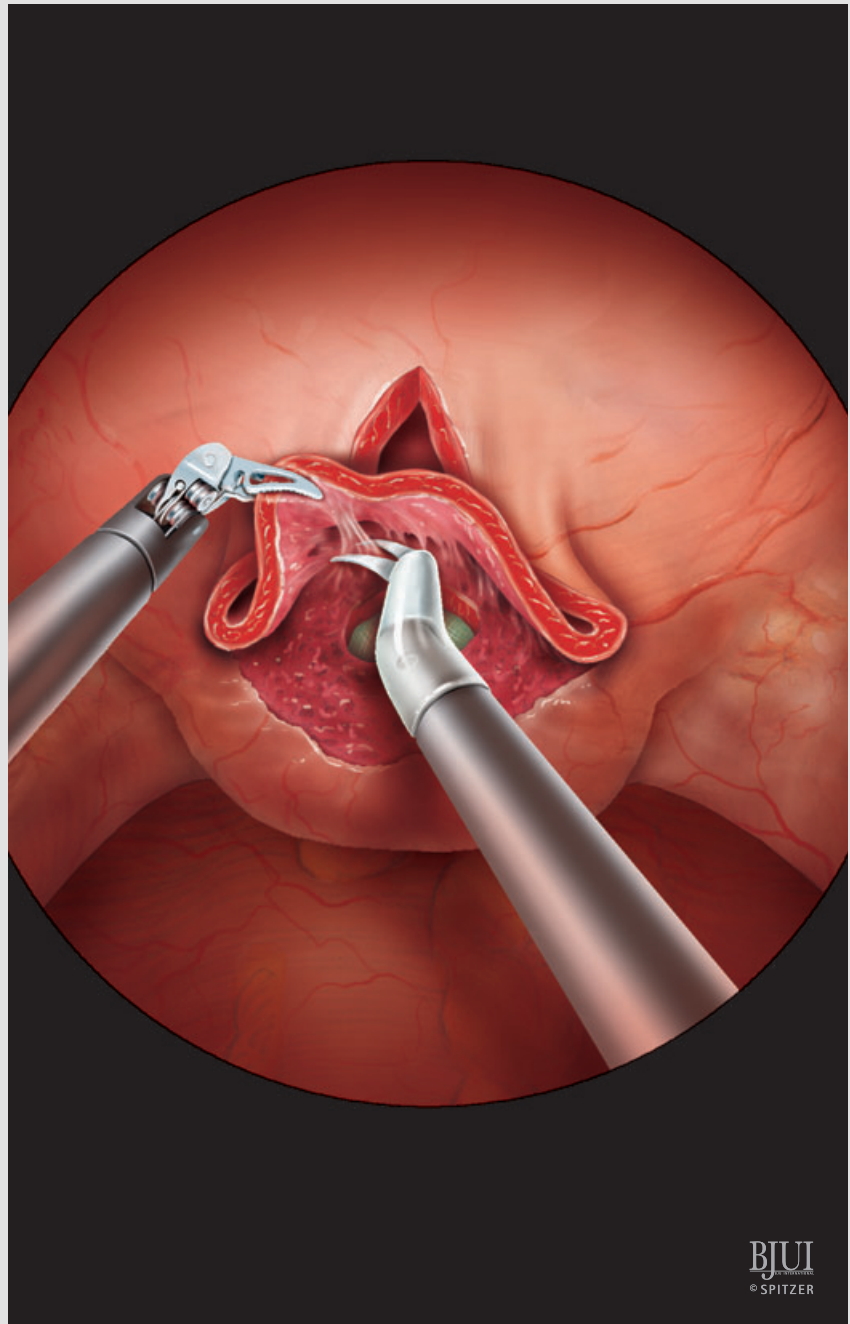
To improve subsequent closure of VVF, the borders of the fistulous tract are widely excised until a lateral margin of viable tissue is created. In doing so, all nonviable and necrotic tissue is completely excised and the communication between bladder and vagina becomes more evident. The excised tissue is sent for histological examination. After removing the sponge retractor, a vaginal tamponade is prepared and applied to prevent pneumoperitoneum loss.



SEPARATION AND MOBILISATION OF THE
BLADDER FROM THE VAGINA**Figure 11**

After performing a generous excision of the fistulous tract, a meticulous dissection follows to separate the vagina from the bladder using robotic scissors and gentle counter traction with the robotic Maryland grasper. Thus, the bladder wall is fully mobilised off the anterior aspect of the vagina. The preplaced ureteric catheters are helpful in identifying the ureteric orifices and preventing inadvertent injury to the ureters. Further mobilisation and disconnection of the bladder from the anterior vaginal wall allows a tension-free closure.

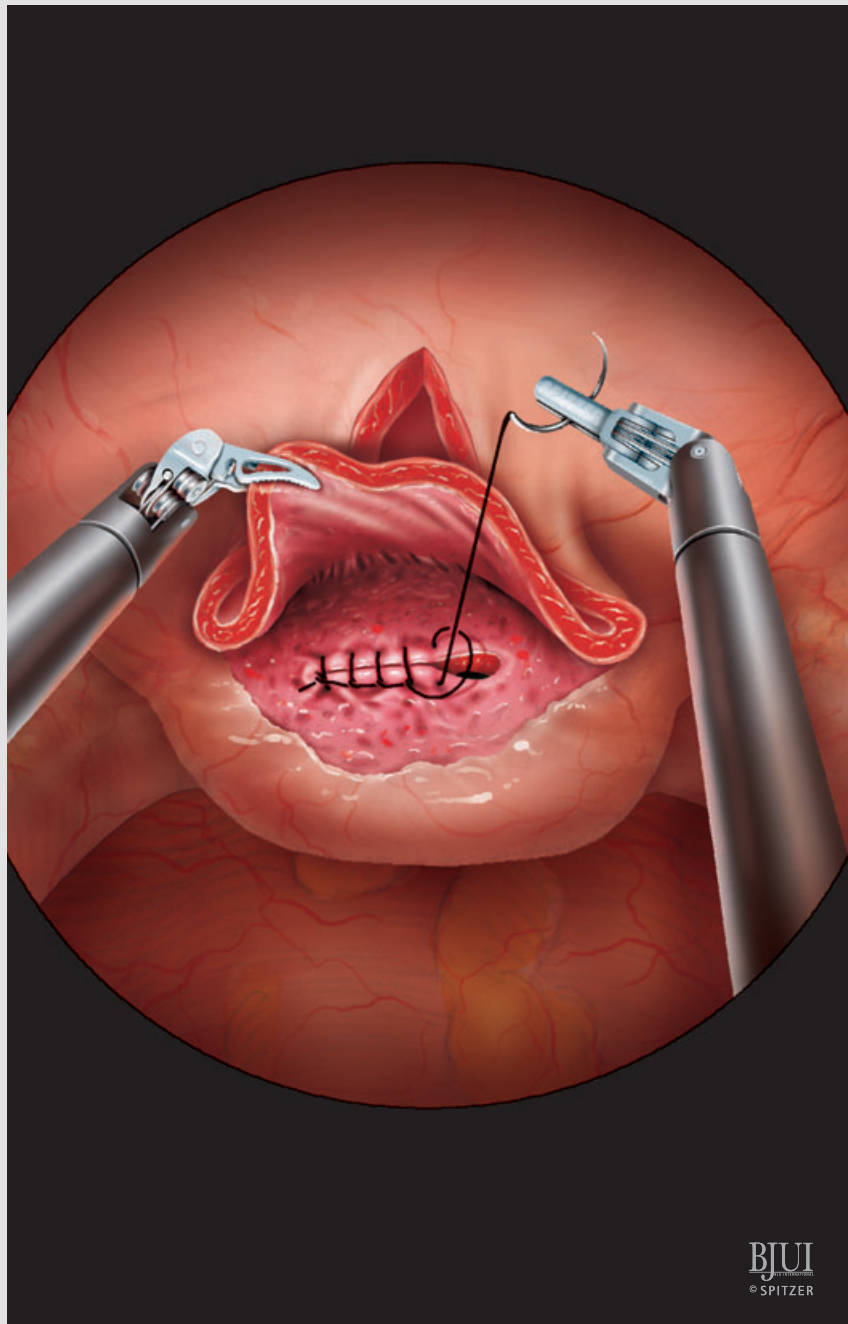
Because the trigone and ureteric orifices invariably lie in close proximity with fistulous edges, it is important to avoid uncontrolled blunt and wide excision, which may hamper subsequent closure. It is preferable to do a slow and careful sharp dissection of the fistulous edges, which must be freshened. Bleeding should be controlled with bipolar cautery, avoiding extensive necrosis of monopolar energy.



REPAIR OF THE FISTULA: CLOSURE OF VAGINA

Figure 12

Beginning with the closure of vagina, the suture line is placed mostly transversely using 3-0 monofilament synthetic absorbable suture as a running locking, watertight suture. Should the size and the orientation of the vaginal hole allow less tension on the closure line, a vertically placed suture line could be acceptable. Maintaining the pressure of pneumoperitoneum after removal of the vaginal tamponade is used as a rough test to check the adequacy and the watertightness of vaginal closure.



MOBILISATION OF INTERPOSITION TISSUE BETWEEN VAGINAL AND BLADDER SUTURE LINES: OMENTUM

Figure 13

Tissue interposition between the bladder and vaginal suture lines is performed preferably using a well-vascularised pedicle of omentum. To reduce tension on the vascular pedicle of omentum and to better mobilise this in the lower abdomen, the patient is placed in an almost horizontal position. In case the omentum is completely retracted in the upper abdomen, it can be better mobilised using laparoscopy, if the robot system is put off, and following the surgical principles of open omentoplasty [11]. Thus, when omentum is present it can be almost always used for interposition between the suture lines.

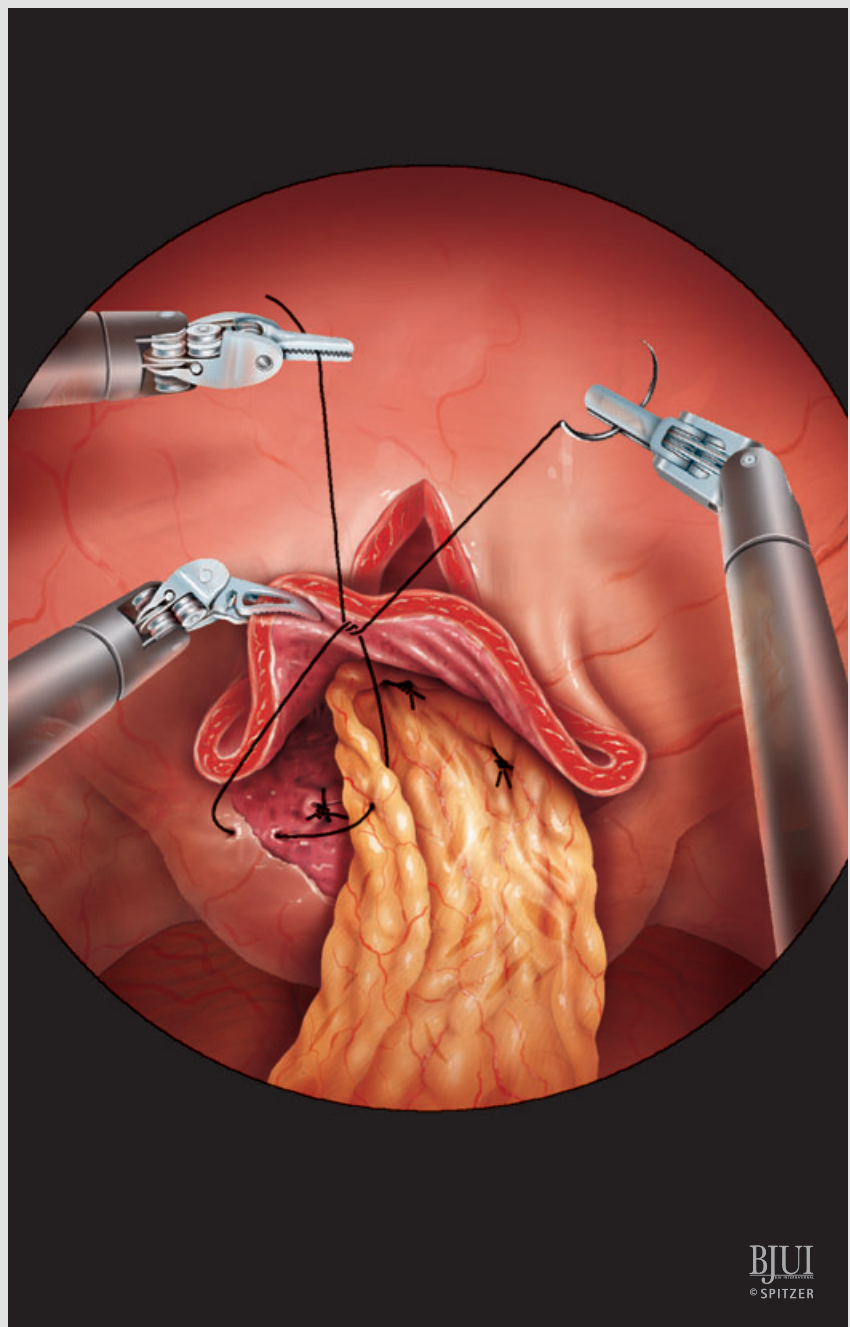
ALTERNATIVES TO OMENTUM AS INTERPOSITION TISSUE BETWEEN VAGINAL AND BLADDER SUTURE LINES

If omentum is unavailable or cannot be adequately mobilised, the epiploic appendices of the sigmoid colon or a peritoneal flap from the nearest anatomical location is used as tissue for interposition.

FIXATION OF INTERPOSITION TISSUE BETWEEN VAGINAL AND BLADDER SUTURE LINES

At the anterior vaginal wall distal to the vaginal closure, a 2-0 polyglactin suture is placed, which is used as a fixation to anchor the interposition tissue.

To avoid any contact between both suture lines and provide stability on fixation, the interposition tissue is anchored with a suture on the resilient vaginal wall and distally to the end of the vaginal closure line. To prevent laxity on fixation, the interposition tissue is additionally fixed left and right on the peritoneal edges of the cystotomy. Thus, the interposition tissue completely covers the suture line of the vagina, forming a triangle; each top of which is fixed on elastic and well-vascularised tissue.



FISTULA REPAIR: BLADDER CLOSURE

Figure 14

After the transversely placed vaginal suturing, the bladder is closed in a vertical manner to minimise the contact surface of suture lines. Bladder closure is initiated at the apex of the incision at the most distal part of cystotomy near to the ureteric orifices. Great care is taken to start the initial knot on the outer bladder surface with a 3-0 monofilament, absorbable suture in one layer and in a running continuous fashion.

If the cystotomy is quite long, the bladder closure can be started from the proximal open bladder edge until the superior-posterior part of bladder is closed.

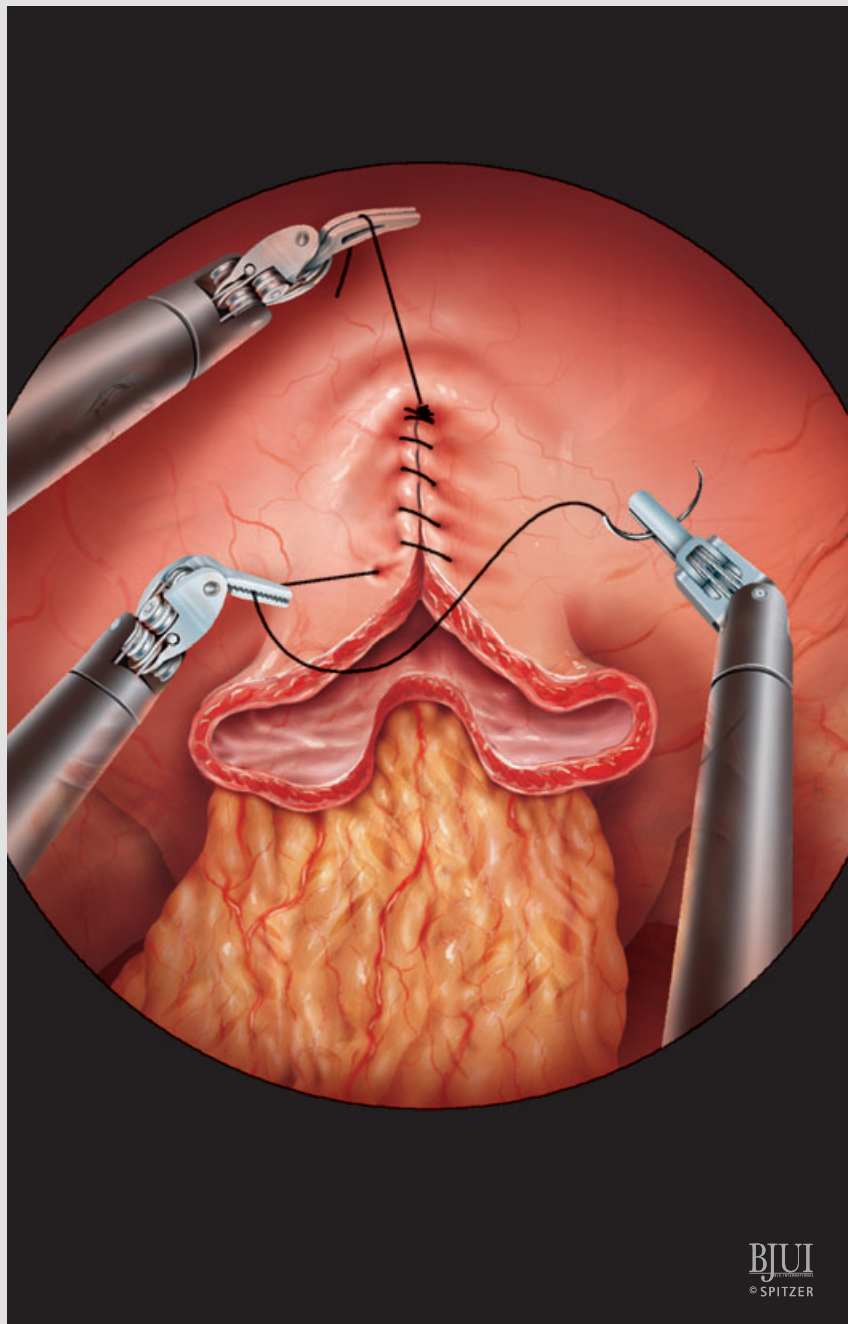
BJUI
© SPITZER

Figure 15

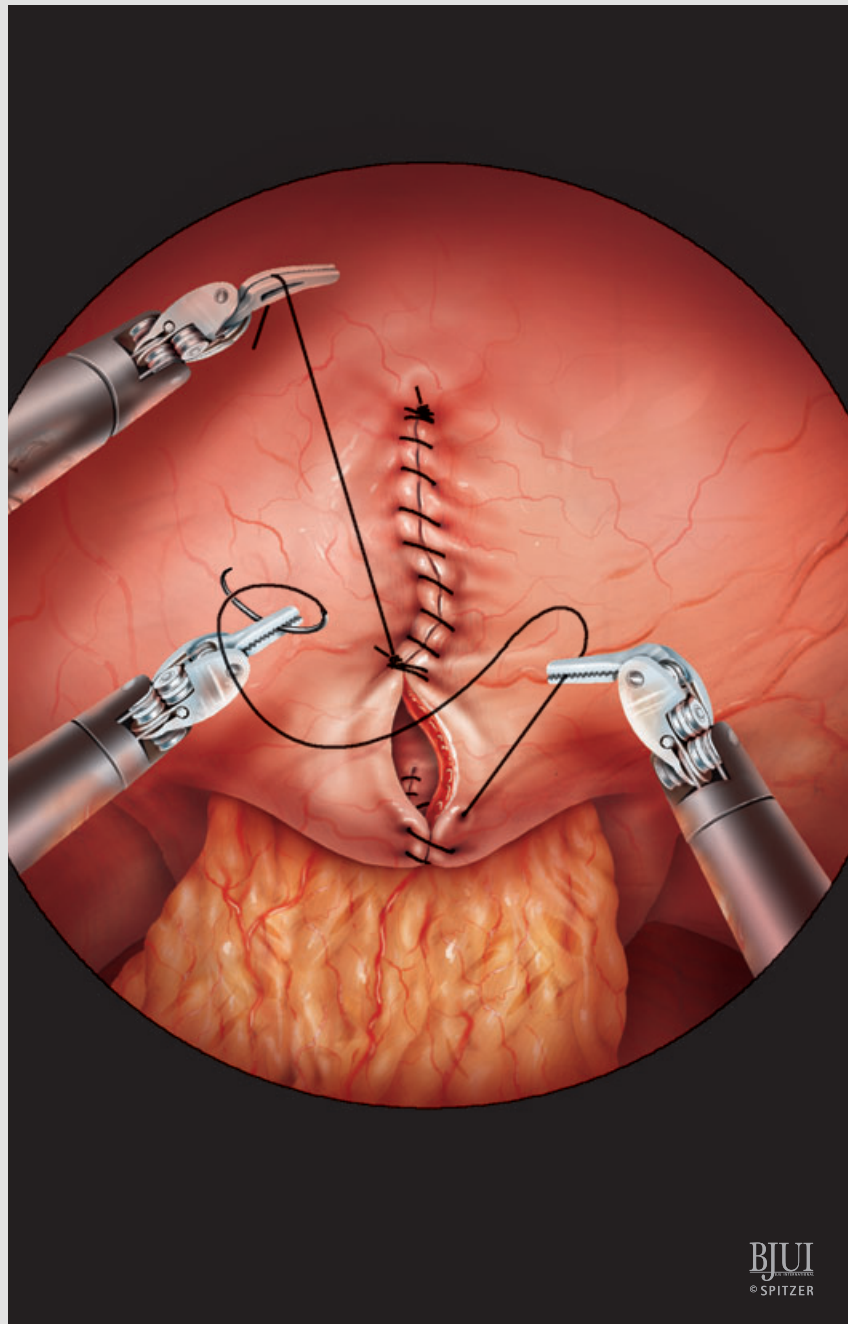
Then, using new suture material, the most distal segment of cystotomy is closed until the two are securely knotted together approximately in the middle of the cystotomy line. In so doing, the proximal suture can be used as traction to provide better exposition and subsequently improved visualisation for the critical part of cystotomy closure near to the ureteric orifices. Additionally, using two separate sutures for cystotomy closure avoids possible laxity of the single suture line.

On finishing bladder closure, water-tightness is confirmed by filling the bladder with 180 mL saline, which is instilled through a 22 F indwelling catheter. In case of any minor leakage, additional interrupted sutures are applied.

No suprapubic cystostomy tube is placed. A Jackson-Pratt drain or alternatively a suction 14-F drain is introduced into the small pelvis in the rectovaginal pouch, through the right robotic port and secured to the skin with a number one silk suture.

FINAL OPERATION STEP: REMOVAL OF TROCARS AND CLOSURE

Reducing the pressure of pneumoperitoneum under 10 mmHg, the robotic and assistant trocars are removed under optical guidance to prevent any bleeding coming from vessels of the abdominal wall. At the end, the fascia of optical trocar (12 mm) is closed with monofilament non-absorbable, number one running suture. The skin is closed by either 4-0 braided polyglactin, subcuticular sutures and sterile strips or metal clips.



BJUI
© SPITZER

POSTOPERATIVE CARE AND FOLLOW-UP

Postoperative care of robotic VVF repair is no different from that of the open procedure [8] and may include the following points:

- 1) The drain is removed on postoperative day (POD) 1 or 2 when drainage fluid is <50 mL in 24 h. The patient is discharged home with an indwelling urethral catheter and two ureteric catheters, which are exteriorized through the urethra and fixed around the urethral catheter with a number one silk suture. During the initial experience, insertion of the ureteric catheters is beneficial mostly because the bladder remains almost completely dry to facilitate the healing process. Thus, they remain in place for 1 week. Gaining more experience, this was deemed unnecessary and dispensed with in subsequent cases, removing the ureteric catheters on POD 1.
- 2) Normally the urethral catheter is removed on POD 14 or 21, depending on the quality of reconstruction and the surgeon's preference. A retrograde cystogram may be performed before removal of the bladder catheter to confirm fistula closure but is not always mandatory. Patients are warned to avoid the use of tampons and refrain from sexual activity for at least 2 months postoperatively.
- 3) Appropriate prophylactic antibiotics are generally given until all tubes are removed. A urine culture is routinely performed after the removal of the transurethral catheter and 2 weeks after the discontinuation of antibiotic prophylaxis. Any UTI or bacteriuria must be treated.
- 4) Great care is taken to secure constant urine flow of the transurethral catheter and ureteric catheters (if present), by preventing clot obstruction and retention. Only when there is suspicion of catheter obstruction, is irrigation of these tubes necessary.
- 5) Early mobilisation and ambulation is encouraged using the principles of fast-track postoperative care: no nasogastric tube, gradual nutrition and mobilisation starting 8 h after the end of the procedure.

FROM SURGEON TO SURGEON

DIFFICULT CASES

By definition, robotic VVF repair is a challenging operation, as fistula formation is

a complication arising from a previous gynaecological operation. Previous abdominal surgeries, especially in the small pelvis, may have created extensive peritoneal adhesions requiring difficult adhesiolysis before inserting the ports. A history of failed attempts of open/abdominal or vaginal repair of VVF, ruptured viscera or peritonitis deserves special caution. The operation becomes more difficult in markedly obese (body mass index >40 kg/m²) women and in those who have had radiation or complicated VVF. Special attention must be paid when accepting women with these factors during early robotic experience.

TIPS AND TRICKS: THINGS TO MAKE ROBOTIC SURGERY EASIER

One of the most important factors in making robotic repair of VVF easier is a consistent and efficient robotic team performing the complete spectrum of robotic urological surgery. In some special conditions, e.g. in the narrow space of cystotomy, the movements of the robotic instruments can be restricted in the dissection and/or reconstruction of VVF near to the ureteric orifices. The experienced assistant can move the robotic arms medially, thereby changing the angle of the instruments.

Using appropriate lenses, 0°, 30° up and 30° down, in various steps of the procedure maximises the visualisation of the operative field and prevents clashing between telescope and instruments in the narrow pelvic space. When severe adhesions are present, the use of a 5-mm EndoEYE™ lens with flexible tip is also recommended to facilitate the adhesiolysis because it has different angles of view and can be used through any trocar.

Generally, the first step for successful treatment outcome of a surgical disease is the correct diagnosis. The proper diagnosis of VVF is supported by clinical evaluation. Office flexible cystoscopy, vaginal examination, three-swab test, retrograde cystourethrography and excretory urography confirm VVF and exclude concurrent ureteric injury or complicated fistula [5]. Ureteric involvement or decreased bladder capacity may necessitate ureter new implantation in the bladder or augmentation cystoplasty, respectively.

If there is any doubt about the timing of VVF repair, it is preferable for surgical treatment to be performed at least 3 months after the initial diagnosis. Although the early repair of VVF could be an attractive option mainly because of the advantage of the immediate improvement in quality of life, the classical strategy is the delayed repair, undertaken after 3–6 months and allowing the tissue of any inflammation to heal and re-vascularise. As the best chance of success is with the first repair, the proper selection of patients for the earliest date for surgery is essential. This necessitates regular follow-up of the bladder and vagina with cystoscopy to exclude active inflammation, such as devitalised tissues, oedema (confirming a destructive process), cystitis or encrustation. When other bladder pathologies (suture, stone and diverticulum) exist, then surgery should be postponed until these problems are resolved.

Because all patients with VVF have undergone at least one previous gynaecological surgery, the access for creating pneumoperitoneum is performed either by open access or alternatively by inserting Veress in the left hypochondrium. In case of previous open surgical repair of VVF, extensive adhesion lyses may have to be performed before repairing the fistula robotically. To facilitate a complete adhesiolysis for safe insertion of robotic trocars, it is sometimes advisable to insert an additional 5-mm port more cephalic and lateral outside the standard trocar positions for better bowel retraction or insertion of special instruments (i.e. ultrasonic shears, Ethicon UltraCision harmonic scalpel coagulating shears, 5.5 mm diameter) for effective and bloodless dissection.

As no thick laparoscopic instruments (e.g. 10-mm clip applier) are necessary, both assistant ports can be 5 mm in diameter to reduce the risk of postoperative bleeding and formation of port hernias. The needles are passed through the 8-mm robotic or 12-mm camera port.

Completely respecting the basic surgical principles of VVF reconstruction is the key factor for a successful closure. However, in our experience, the two most important surgical principles for a successful outcome are the interposition of well-vascularised tissues, preferably omentum, and adequate postoperative bladder drainage.

Interposition of omentum is absolutely the first choice, especially in post-irradiation conditions. Only if the omentum is resected or unavailable because of extensive adhesions after previous surgeries in the upper abdomen, should another tissue flap be placed between the suture lines. To facilitate the mobilisation of omentum, the following tricks may be applied:

- i. the patient is placed at horizontal or even reversed Trendelenburg position
- ii. using the 30° down lens and the help of the bedside assistant, who grasps the omentum with atraumatic laparoscopic grasper
- iii. when omentum is not long enough to reach the area of VVF in the small pelvis, a conventional laparoscopic omentoplasty detaching the great epiploon from the great gastric curvature with creation of omental flap is mandatory. The use of ultrasonic shears along with the assistance of a laparoscopic surgeon who is familiar with advanced laparoscopy in the upper abdomen (especially gastric sleeve or resection) is crucial in laparoscopic omentoplasty.

If it is impossible to interpose healthy tissue between the suture lines because of significant intraperitoneal adhesions, which may preclude access to suitable tissue, we tend to use a Martius flap via an additional vaginal incision or alternatively an absorbable fibrin sealant patch (TachoSil™ patch, Baxter Healthcare Corporation Westlake Village, CA, USA). However, the use of a biological patch or sealant is questionable. In using this biological sealant in two of our patients, we had one case with fistula recurrence and no longer recommend it.

In our experience, it is essential to keep the bladder completely dry to provide an optimal healing process. If inserting ureteric catheters, there is the option of removing these early without additional intervention (cystoscopy) or of keeping them for a longer

period if there is suspicion of inadequate VVF closure.

In challenging cases, especially if the fistula is quite large and in close proximity to a ureteric orifice, it is difficult to perform closure of the cystotomy in the manner mentioned above. In such cases, a Z-form bladder wall reconstruction or a Y-V-plasty can be performed to provide a tension-free suture line. To prevent suture laxity, the running sutures are intermittently locked or knotted.

To relieve the tension on the sutures of cystotomy closure, especially in cases of recurrent VVF where the bladder has lost elasticity, the paravesical space can be opened bilaterally, leaving the bladder suspended from the umbilical ligaments.

There is an additional procedure that can be performed to gain better visualisation of the bladder for its dissection with the vagina that has not been described in this article: sutures are placed in the lateral aspects of the bladder with a straight needle, so that they can be exteriorised and counter traction can be made permanently, this manoeuvre is particularly suitable in complex VVFs. The watertight cystotomy closure is best confirmed by filling the bladder with 180 mL saline with Methylene blue, so the specific location of any leakage can be clearly identified. If it is planned to remove the ureteric catheters postoperatively (on POD 1 or thereafter), it is important to ensure that the catheters are easily mobilised and not attached with any sutures after bladder closure. After having gained more experience with robotic repair of VVF, we normally remove the ureteric catheters during the same procedure while the patient is still under anaesthesia.

REFERENCES

- 1 Miller EA, Webster GD. Current management of vesicovaginal fistulae. *Curr Opin Urol* 2001; **11**: 417–21
- 2 Hilton P, Ward A. Epidemiological and surgical aspects of urogenital fistulae: A review of 25 years' experience in southeast Nigeria. *Int Urogynecol J Pelvic Floor Dysfunct* 1998; **9**: 189–94
- 3 Thomas K, Williams G. Medicolegal aspects of vesicovaginal fistulae. *BJU Int* 2000; **86**: 354–9
- 4 Hilton P. Vesico-vaginal fistula: New perspectives. *Curr Opin Obstet Gynecol* 2001; **13**: 513–20
- 5 Romics I, Kelemen Z, Fazakas Z. The diagnosis and management of vesicovaginal fistulae. *BJU Int* 2002; **89**: 764–6
- 6 Blaivas JG, Heritz DM, Romanzi LJ. Early versus late repair of vesicovaginal fistulas: vaginal and abdominal approaches. *J Urol* 1995; **153**: 1110–3
- 7 Lee RA, Symmonds RE, Williams TJ. Current status of genitourinary fistula. *Obstet Gynecol* 1998; **72**: 313–9
- 8 Chapple C, Turner-Warwick R. Surgery Illustrated – Surgical Atlas. Vesico-vaginal fistula. *BJU Int* 2005; **95**: 193–214
- 9 Sotelo R, Mariano MB, Garcia-Segui A, et al. Laparoscopic repair of vesicovaginal fistula. *J Urol* 2005; **173**: 1615–8
- 10 Hemal AK, Kolla SB, Wadhwa P. Robotic reconstruction for recurrent supratrigonal vesicovaginal fistulas. *J Urol* 2008; **180**: 981–5
- 11 Paparel P, Caillot J-L, Perrin P, Ruffion A. Surgery Illustrated – Focus on details. Surgical principles of omentoplasty in urology. *BJU Int* 2007; **99**: 1191–6

Correspondence: Vassilis Poulakis, Department of Urology, Metropolitan Hospital, Athens, Greece.
e-mail: vpoulakis@hotmail.com

Abbreviations: VVF, vesicovaginal fistula; 3-D, three-dimensional; POD, postoperative day.